

Inflammatory Bowel Disease in Young Adult

Dian Daniella*, Janto Simkoputera**, Candra Wiguna**

*General Practitioner, Siloam Hospitals Kebon Jeruk, Jakarta

**Department of Gastroenterology, Siloam Hospitals Kebon Jeruk, Jakarta

Corresponding author:

Dian Daniella. Siloam Hospitals Kebon Jeruk. Jl. Perjuangan No. Kav 8 Jakarta Indonesia. Phone/facsimile: +62-21-25677888. E-mail: dian.daniella@gmail.com

ABSTRACT

Inflammatory bowel disease is a chronic inflammatory disease that consist of Crohn's disease and ulcerative colitis. A dramatic increase in the prevalence of inflammatory bowel disease (IBD) within developing countries including in Asia makes IBD a substantial global medical burden and modern refractory disease, and it is imperative that Asian healthcare systems especially physician are aware of this and familiar with the clinical manifestation and management. The aim of this case report is to present a case of IBD in young adult in Indonesia. Patient came with complaint of chronic diarrhea and had seen multiple doctor without improvement. Inflammatory bowel disease should always be considered in patient with chronic diarrhea with or without extraintestinal manifestation especially after poor response of usual antidiarrheal medication. Diagnosing of IBD is based on clinical manifestation, physical examination, laboratory result and endoscopy. Until now, ileocolonoscopy and biopsy is the most accurate diagnostic modality for IBD and can be used to differentiate between ulcerative colitis and Crohn's disease. Treatment of IBD are drugs such as mesalazine until surgery based on the severity or complication of disease.

Keywords: inflammatory bowel disease, colitis ulcerative, crohn's disease, diarrhea

ABSTRAK

Inflammatory bowel disease (IBD) adalah penyakit kronis yang terdiri dari penyakit Crohn dan kolitis ulserativa. Peningkatan dramatis dalam prevalensi dari IBD di negara-negara berkembang termasuk di Asia menjadikan IBD sebagai beban medis global yang substansial, dan sangat penting untuk sistem kesehatan Asia terutama dokter menyadari hal ini dan mengetahui manifestasi klinis dan manajemen dari IBD. Tujuan dari laporan kasus ini adalah untuk menyajikan kasus IBD pada dewasa muda di Indonesia. Pasien datang dengan keluhan diare kronis dan telah berobat ke banyak dokter sebelumnya tanpa adanya perbaikan. Inflammatory bowel disease harus selalu dipertimbangkan pada pasien dengan diare kronis dengan atau tanpa manifestasi ekstraintestinal terutama setelah respon yang buruk dari obat antidiare biasa. Diagnosis IBD didasarkan pada manifestasi klinis, pemeriksaan fisik, hasil laboratorium dan endoskopi. Hingga saat ini, ileocolonoskopi dan biopsi adalah modalitas diagnostik paling akurat untuk IBD dan dapat digunakan untuk membedakan antara kolitis ulserativa dan penyakit Crohn. Tatalaksana IBD adalah dengan obat-obatan seperti mesalazine sampai operasi berdasarkan tingkat keparahan atau komplikasi penyakit.

Kata kunci: inflammatory bowel disease, colitis ulseratif, penyakit crohn, diare

INTRODUCTION

Inflammatory bowel disease (IBD) is a chronic inflammatory disease that involves the gastrointestinal tract and resulted from combination of genetic susceptibility, environmental exposure and dysregulated response to intestinal microbiota with an alternating relapsing and remitting clinical progression.^{1,2} Inflammatory bowel disease consist of Crohn's disease (CD) and ulcerative colitis (UC).¹ Ulcerative colitis is restricted to the mucosa of the colon, whereas the lesions in CD are often discontinuous, occur across the entire wall of the organ (transmural), and involve any part of the gastrointestinal tract from mouth to anus.³

The highest occurrence of IBD is seen in developed countries in North America and Europe, affecting up to 0.5% of the general population.¹ Other than developed countries, developing countries such as countries in Asia has also been experiencing IBD.¹ Ng et al state that in the past two decades, Asia has been experiencing a significant increase in IBD incidence with highest prevalence in East and South Asia.¹

In 2012, incidence rate in Indonesia for UC is 0.55 per 100,000 persons and CD 0.33 per 100,000 persons. A dramatic increase in the prevalence of IBD within developing countries including in Asia makes IBD a substantial global medical burden and modern refractory disease, and it is imperative that Asian healthcare systems especially physician are aware of this and familiar with the clinical manifestation and management.^{1,2} The aim of this case report is to present a case of IBD in young adult in Indonesia.

CASE ILLUSTRATION

A sixteen year old boy came to the hospital with chief complaint of diarrhea for 2 months. The characteristic of diarrhea was porridge-like to liquid, around 3 to 5 times a day, yellowish, with no blood. There was no fever, but patient complaint of epigastric pain with slight nausea and no vomiting. He lost his appetite and admit to lost 20 kilograms in 2 months. He is underweight. He already seen multiple doctors beforehand and was diagnosed with gastroenteritis and antibiotic, probiotic and anti-diarrhea was given but there was no improvement (diarrhea and weight loss persist). Around a month before, he complained of pain in his perianal region and felt a lump in his perianal region. No joint pain, joint swelling, erythema or red eyes and blurry vision. There was no family history of similar disorder, atopy, drug abuse and sexual activity.

At admission, the patient malnourished with normal vital sign. Bowel sound was increased with no abdominal tenderness. We found perianal abscess. Other physical sign were normal.

Laboratory results revealed hemoglobin (Hb) 10.4 g/dL (13.0-18.0), hematocrit 31.8% (40-54), white blood cell (WBC) 14,000/uL (4,000-10,000), platelets 536,000/uL (150,000-400,000), C-reactive protein (CRP) 90.4 mg/L (< 5), erythrocyte sedimentation rate (ESR) 54 mm/hour (0-15), mean corpuscular volume (MCV) 69.4 fL (81-96), mean corpuscular hemoglobin (MCH) 22.7 pg (27-36), mean corpuscular hemoglobin concentration (MCHC) 32.1 g/L (31-37), differential count 0/0/1/88/10/1, aspartate aminotransferase (AST) 13 mg/dL (5-34), alanine aminotransferase (ALT) 9 mg/dL (< 55), albumin 3.1 g/dL (3.5-50.0), creatinine 0.8 mg/dL (0.7-1.3), serum iron 14 ug/dL (65-175), total iron binding capacity (TIBC) 185 ug/dL (71-504), transferrin saturation 7.6% (15-50), natrium 134 mmol/L (134-145), kalium 3.6 mmol/L (3.5-5.5), chloride 101 mmol/L (97-111), blood glucose 115 mg/dL (< 200), carcinoembryonic antigen (CEA) 1.16 ng/mL (0-5.2), FT4 1.29 pmol/L (1.1-1.8), FT3 2.4 pmol/L (2.6-5.1), fecal calprotectin > 2100 (< 50), seramoeba (-), HbsAg (-), anti-HCV (-) with IgM and IgG *H. pylori* (-).

Stool analysis revealed sign of gastrointestinal infection with occult blood test positive. Colonoscopy showed perianal abscess with internal hemorrhoid grade I-II, hyperemia, erosion and superficial ulcers in most mucosal parts of rectum to caecum, mucosa of ileum terminalis appears normal with conclusion of suggestive ulcerative colitis (Figure 1). Colon biopsy was performed in several parts and revealed irregular superficial epithelium with multiple erosive and ulcerative tissue, hyperemic lamina propria with multiple chronic and acute inflammatory cells, distorted crypts and multiple crypt abscess, which disclosed as active chronic colitis with crypt destruction and no sign of malignancy. This findings can be found in IBD.

Based on the data above, diagnosis was made, which is inflammatory bowel disease (ulcerative colitis), iron deficiency anemia and malnutrition. He was then given ringer lactate 1500cc/24 hour, levofloxacin 1 x 750 mg IV, mesalazin 500 mg three times daily orally, methylprednisolone 125 mg once daily IV, rebamipide 100 mg three times daily, PPI two times daily IV, iron supplement 2 times daily orally, folic acid mg two times daily orally, and antiemetic. Parenteral nutrition of 1440 kkal/day was given. Patient was consulted with surgeon and abscess was incised and drainage.

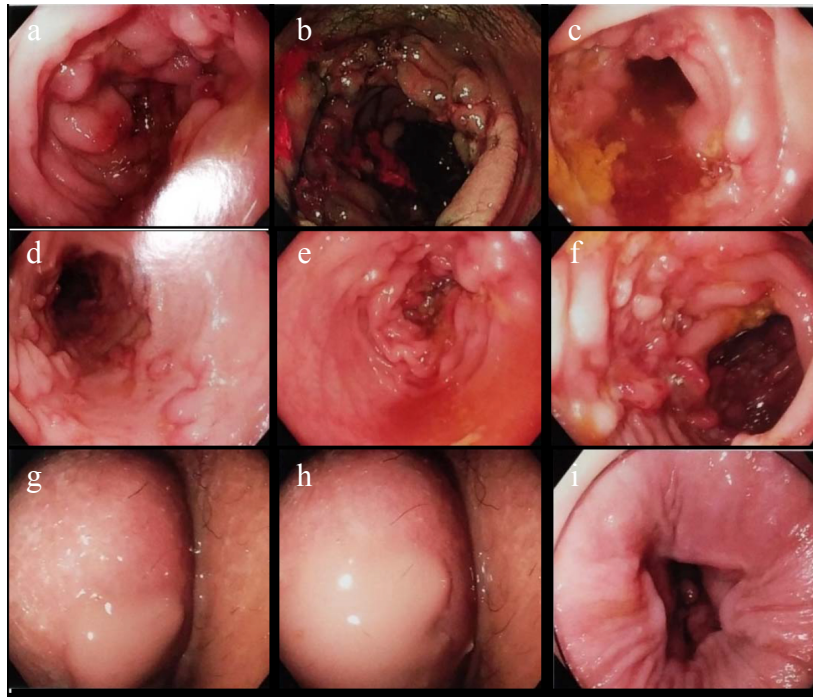


Figure 1. Colonoscopy (a,b,c,d,e,f: ulcerative colitis; g,h: perianal abscess; i: internal hemorrhoid)

The operation was uneventful and patient went home with mesalazine 3 x 500 mg, methylprednisolone 2 x 4 mg, rebamipide 3 x 100 mg, iron supplement 1 x 1 and folic acid 2 x 5 mg. He came back to us one week later and his symptoms was getting better with complained of diarrhea around 1-2 times a day. Reevaluation of therapy was planned to be performed after one week.

DISCUSSION

This case report present a case of male young adult with IBD. It took two months until the patient was diagnosed with IBD. This is probably due to unfamiliarity of IBD in Indonesia. The diagnosis of IBD is achieved by combining clinical, laboratory, endoscopic, histological, and radiological findings.⁴ Autoimmune are widely considered as the cause of IBD, as most patient with IBD has a individual or family history of vasculitis or systemic lupus erythematosus.² Nevertheless, recent studies stated that IBD resulted from combination of genetic susceptibility, environmental exposure and dysregulated response to intestinal microbiota.^{1,2} In this case, the patient did not have an individual nor family history of autoimmune disease, but IBD should still be considered as it could be result from combination of genetic and environment.

Inflammatory bowel disease can present as bloody diarrhea, vague abdominal pain, diarrhea, unexplained anemia, fever, weight loss, or growth retardation, with bloody diarrhea as the most common presenting

symptom in UC (in 50% patient).⁵ In this patient, patient came with chronic diarrhea, abdominal pain, mild nausea, weight loss with perianal abscess. Perianal disease (PAD) in IBD has always been linked to CD and can be present in 26% of CD patients.⁶ Contrary to that, recent study by Yabana et al. stated that around 5% patient with UC may develop PAD and suggest that UC patient with PAD should be given steroid, because PAD indicating more severe or persistent rectal inflammation.⁶ Extraintestinal manifestation of IBD can affect joint, skin, eyes, such as peripheral arthritis, erythema nodosum, and episcleritis.⁷ Patient didn't complain of extraintestinal manifestation and this is probably due to according to Levine et al, extraintestinal manifestations may present at diagnosis only in 6% to 23% of children with a higher frequency in those more than six years.⁵

Multiple laboratory tests may be abnormal in IBD. These patient usually have decreased hemoglobin or elevated total white cell count and platelet count, and high inflammatory markers, such as CRP and ESR that reflect systemic patient responses.^{4,5} Patient usually has low serum albumin that indicate protein losing enteropathy.⁵ This patient has microcytic hypochromic anemia, leukocytosis and thrombocytosis with high ESR and CRP. Other than that, patient also has hypoalbuminemia. All of these findings fit the description of laboratory test in IBD patients.

Revised Porto Criteria for the Diagnosis of Inflammatory Bowel Disease in Children and

Adolescents stated that fecal calprotectin is a more sensitive tool for diagnosis of IBD than inflammatory markers such as CRP and ESR.⁵ Calprotectin is a calcium and zinc binding protein mostly derived from neutrophils and monocytes.⁴ It has been shown to be a reliable marker for assessing IBD disease activity and in predicting mucosal healing and risk of relapse.⁸ In this patient, his fecal calprotectin is very high (> 2100 (< 50)) that stated there is intestinal inflammation.⁵ Stool analysis revealed sign of gastrointestinal infection with occult blood test positive, that fit the description of IBD.

In recent years, ileocolonoscopy (and biopsies) is the most essential part of the diagnostic workup in pediatric IBD and essential in differentiating UC from CD.^{4,5,9} The most reliable feature to diagnose UC is continuous mucosal inflammation of the colon, starting from the rectum, without small bowel involvement, and without granulomas on biopsy.⁵ Colonoscopy in this patient showed perianal abscess with internal hemorrhoid grade I-II, hyperemia, erosion and superficial ulcers in most mucosal parts of rectum to caecum, mucosa of ileum terminalis appears normal with conclusion of suggestive ulcerative colitis.

Colon biopsy revealed irregular superficial epithelium with multiple erosive and ulcerative tissue, hyperemic lamina propria with multiple chronic and acute inflammatory cells, distorted crypts and multiple crypt abscess, which disclosed as active chronic colitis with crypt destruction and no sign of malignancy. Disturbed crypt architecture, cryptitis and crypt abscess are signs of chronicity.⁵

In a country with tuberculosis is endemic, possibility of intestinal tuberculosis (ITB) should be considered. ITB and IBD are chronic granulomatous disorders with phenotypic similarities that make the differentiation between them a challenging task. ITB is characterized by numerous large, well-defined granulomas, especially in the submucosa and in the granulation tissue around the ulcers, often with caseation and confluence. TB granulomas has more than four sites of granulomatous inflammation per site, caseation and a band of epithelioid histiocytes in ulcer bases and location of granulomas in the caecum. The granuloma in IBD are fewer, smaller, never confluent or caseating and seldom found in the submucosa.¹⁰

Other modalities that can be used is ultrasound. Ultrasound detects, locates, and characterizes inflammation of the bowel wall and assesses per-intestinal abnormalities, with a good negative predictive value for IBD.⁵ Magnetic resonance imaging

(MRI) can estimate both the extent of intestinal inflammation and the degree of damage (stricturing or penetrating disease).⁵

Medication and surgery could be used in managing IBD.⁸ Generally, a step-up approach, in which a conventional therapy is added if first-line treatment is ineffective, has been preferred for many years.⁸ However, studies have shown that a top-down approach, in which a potent agent is started at the early stage of the disease, may be associated with reduced hospitalization and surgeries in IBD patients. 5-Aminosalicylic Acid (5-ASA/Mesalazine) are first-line treatment for the induction and maintenance of remission in mild to moderate UC.⁸

Corticosteroid is effective in acute patient.⁸ Corticosteroid oral such as prednisone and methylprednisolone or corticosteroid enema should be given. In severe case, corticosteroid parenteral should be given. Budesonide orally or enema is a non-systemic glucocorticoid that have minimal systemic effect with high concentration in intestinal that could be used. Mean dosage use until remission is achieved is usually 40-60 mg prednisone with tapering dose after remission achieved in 8 to 12 weeks.¹¹

Immune-modifying agents such as 6-mercaptopurine or azathioprine is used in approximately 6% of cases, with only 1% of patients receiving methotrexate.⁸ This low use of immune-modifying agents is likely to be due to the risk of severe adverse effects and the requirements for blood test monitoring.⁸ Known adverse events of this medication include leucopenia and transaminases increase, allergic reactions, mild (nausea and dyspepsia) or severe (acute pancreatitis) gastrointestinal adverse effects, increased risk of or non-melanoma skin cancer.⁸

Rebamipide is an amino acid derivative of 2 (1H)-guinoione that is a gastric mucosal protective and ulcer-healing agent. Rebamipide is proven to be useful and safe in patient with IBD especially in corticosteroid-refractory patient.¹² Furuta et al conducted a clinical trial with 21 patient with IBD. It was found that rectal administration of rebamipide twice a day for 3 weeks led to clinical remission for 53% patient with no side effect. This is due to anti-inflammatory activity that rebamipide has.¹³ Other than that, rebamipide healed intestinal injury by enhancing the migration of intestinal epithelial cells.¹⁴

Patient was given mesalazine and corticosteroid with other supportive treatment and showed positive effect. The international consensus group recommended that disease activity be reassessed at three to six after the

start of therapy in UC with colonoscopy.⁹ Spiceland stated that patients with IBD have an increased risk of developing colorectal cancer compared to the general population, therefore, surveillance endoscopy has been recommended in patients with IBD beginning eight years after diagnosis.⁹

Inflammatory bowel disease should always be considered in patient with chronic diarrhea with or without extraintestinal manifestation especially after poor response of usual antidiarrheal medication. Ileocolonoscopy and biopsy is the most accurate diagnostic modality for IBD with other helpful modalities such as laboratory, stool and imaging test. Treatment of IBD are drugs such as mesalazine until surgery based on the severity or complication of disease.

ACKNOWLEDGEMENT

The author would like to thank Kandi Chandra from Department of Gastroenterology Siloam Hospitals Kebon Jeruk for performing colonoscopy and Welly Hartono from Department of Pathology Anatomy Siloam Hospitals Kebon Jeruk for analyzing colon biopsy result.

REFERENCES

1. Ng WK, Wong SH, Ng SC. Changing epidemiological trends of inflammatory bowel disease in Asia. *Intest Res* 2016;14:111.
2. Yu Y, Zhu S, Li P, Min L, Zhang S. *Helicobacter pylori* infection and inflammatory bowel disease: a crosstalk between upper and lower digestive tract. *Cell Death Dis* 2018;9:961.
3. Wong S-Y, Cadwell K. There was collusion: Microbes in inflammatory bowel disease. Evans MJ, editor. *PLOS Pathog* 2018;14:e1007215.
4. Rokkas T, Portincasa P, Koutroubakis IE. Fecal Calprotectin in Assessing Inflammatory Bowel Disease Endoscopic Activity: A Diagnostic Accuracy Meta-analysis. *J Gastrointest Liver Dis* 2018;27:299-306.
5. Levine A, Koletzko S, Turner D, Escher JC, Cucchiara S, de Ridder L, et al. The ESPGHAN Revised Porto Criteria for the Diagnosis of Inflammatory Bowel Disease in Children and Adolescents: *J Pediatr Gastroenterol Nutr* 2014;58:795-806.
6. Zabana Y, Domselaar M, Gracia-Planella E, Manosa M, Roman AL, Gordillo J, et al. Perianal disease in patients with ulcerative colitis: A case-control study. *J Crohns Colitis* 2011;5:338-41.
7. Vavricka SR, Schoepfer A, Scharl M, Lakatos PL, Navarini A, Rogler G. Extraintestinal Manifestations of Inflammatory Bowel Disease: *Inflamm Bowel Dis* 2015;21:1982-92.
8. Arnott I, Rogler G, Halfvarson J. The Management of Inflammatory Bowel Disease in Elderly: Current Evidence and Future Perspectives. *Inflamm Intest Dis* 2017;2:189-99.
9. Spiceland CM, Lodhia N. Endoscopy in inflammatory bowel disease: Role in diagnosis, management, and treatment. *World J Gastroenterol* 2018;24:4014-20.
10. Navaneethan U, Cherian J, Prabhu R, Venkataraman J. Distinguishing tuberculosis and *Crohn's disease* in developing countries: How certain can you be of the diagnosis? *Saudi J Gastroenterol* 2009;15:142.
11. Djojongrat D. Inflammatory Bowel Disease: Alur Diagnosis and Pengobatannya di Indonesia. In: *Buku Ajar Ilmu Penyakit Dalam*. 5th ed. Jakarta: Interna Publ.p.591-7.
12. Naito Y, Yoshikawa T. Rebamipide: a gastrointestinal protective drug with pleiotropic activities. *Expert Rev Gastroenterol Hepatol* 2010;4:261-70.
13. Furuta R, Ando T, Watanabe O, Maeda O, Ishiguro K, Ina K, et al. Rebamipide enema therapy as a treatment for patients with active distal ulcerative colitis. *J Gastroenterol Hepatol* 2007;22:261-7.
14. Takagi T. Rebamipide promotes healing of colonic ulceration through enhanced epithelial restitution. *World J Gastroenterol* 2011;17:3802.